

Contents lists available at [SciVerse ScienceDirect](http://www.sciencedirect.com)

Psychiatry Research: Neuroimaging

journal homepage: www.elsevier.com/locate/psychresns

White matter microstructural abnormalities in patients with late-onset schizophrenia identified by a voxel-based diffusion tensor imaging

Liping Chen^{a,b}, Xiaogang Chen^{a,*}, Weiqing Liu^a, Qifeng Wang^c, Tianzi Jiang^c, Jicai Wang^{a,d},
Xiuyan Wang^a, Bing Zhou^a, Jinsong Tang^{a,*}

^a Institute of Mental Health, the Second Xiangya Hospital, Central South University, Changsha, Hunan 410011, PR China

^b The Dalian 7th people's hospital, Dalian, Liaoning 116023, PR China

^c National Laboratory of Pattern Recognition, Institute of Automation, Chinese Academy of Sciences, Beijing 100190, PR China

^d Department of Psychiatry, the First Affiliated Hospital of Kunming Medical College, Kunming, Yunnan 650032, PR China

ARTICLE INFO

Article history:

Received 22 October 2011

Received in revised form

2 March 2012

Accepted 24 May 2012

Keywords:

Diffusion tensor imaging

Late-onset schizophrenia

Fractional anisotropy

White matter

ABSTRACT

Reduced fractional anisotropy (FA) has been previously found in diffusion tensor imaging (DTI) studies of white matter in schizophrenic patients. However, there are no reports in the literature that address FA alterations in late-onset schizophrenia (LOS). The current study measured FA in whole white matter and subsequently analyzed its association with psychotic symptoms in LOS. DTI was carried out in 20 patients with LOS and 17 age-, gender- and education-matched healthy subjects. Fractional anisotropy in different areas of white matter was compared between groups using a voxelwise analysis after inter-subject registration to standard Montreal Neurological Institute (MNI) space. Psychotic symptoms were assessed using the Positive and Negative Syndrome Scale (PANSS). Cognitive functions were measured using the Wisconsin Card Sorting Test (WCST), the Digit Span Test, and the Trail-making Test. Significant reduction in FA was found in the left parietal lobe and right posterior cingulum in LOS patients compared with healthy subjects. Significant deficits in cognitive functions were observed in LOS. No significant correlation was found between FA value and PANSS scores, cognitive test scores, age, or antipsychotic medication dosages in LOS patients. Our study suggests that abnormalities in white matter integrity may contribute to the pathophysiology of LOS. However, these microstructural abnormalities provided no evidence for the emergence of psychotic symptoms in LOS.

© 2012 Elsevier Ireland Ltd. All rights reserved.

1. Introduction

Despite the proposal of several different age cutoffs in the literature to define late-onset schizophrenia, patients who develop schizophrenia or schizophrenia-like symptoms as older adults (> 40 years) are often seen in clinical practice. The percent of schizophrenic patients whose illness first emerged after the age of 40 is 23.5%, while the 1-year prevalence rate is 0.6% for ages 45 to 64, and the incidence rate of schizophrenia with first onset after 44 years of age is 12.6 per 100,000 population per year (reviewed by Howard et al., 2000). Currently, abnormalities in white matter are thought to contribute to the pathophysiology of schizophrenia. However, most reported white matter abnormalities were identified in early-onset schizophrenia or chronic schizophrenia (Pantelis et al., 2005; Rajji et al., 2009; Tang et al., 2010). Relatively,

there is much less information regarding white matter abnormalities in late-onset schizophrenia.

Recent findings derived in neuropathological and neuroimaging studies suggest the involvement of cerebral white matter in the pathophysiology of schizophrenia (Friedman et al., 2008; Chan et al., 2010; White et al., 2011). Neuroimaging studies on white matter abnormalities of schizophrenia are mainly focused on volumetric and diffusion anisotropy changes. Diffusion tensor imaging (DTI) is a non-invasive magnetic resonance imaging (MRI)-based technique that provides information about the molecular diffusion of water within tissues and allows us to characterize intrinsic features of tissue microstructure and microdynamics (Basser, 1995). Diffusion anisotropy of white matter derived from DTI is thought to originate from the specific organization of bundles of myelinated axonal fibers running in parallel. Among the different indices for quantifying diffusion anisotropy, fractional anisotropy (FA) is the most widely used informative parameter to evaluate the integrity of fiber tracts and myelination of neural axons in white matter (Beaulieu, 2002). Reduction in FA is thought to be related to disruption of microstructure of white matter and fiber tracts.

* Corresponding author. Tel.: +86 731 85531571; fax: +86 731 85531571.

E-mail addresses: chenxghn@gmail.com (X. Chen), tangjinsonghn@gmail.com (J. Tang).

Studies with DTI have demonstrated significant alterations in the anisotropy of white matter in schizophrenic patients compared with healthy controls. For example, DTI studies of patients with first-episode schizophrenia have shown lower *FA* in the internal capsule, middle frontal gyrus, and superior temporal gyrus (Szeszko et al., 2008). Previous studies demonstrated a significant decrease in *FA* in the genu of the corpus callosum in patients with chronic schizophrenia, but not in patients with first-episode schizophrenia (Kong et al., 2011). In contrast, a significant decrease in *FA* was found in the right anterior cingulum of patients with early-onset schizophrenia (Tang et al., 2010). These inconsistent findings in *FA* may reflect heterogeneous patients in samples, including differences in onset age, duration of illness, number of acute episodes, medication exposures, and methodological differences in DTI. For example, first-episode and chronic schizophrenia samples may include patients with early-onset and/or late-onset schizophrenia. However, patients with early-onset and first-episode schizophrenia demonstrated severe cognitive deficits compared with patients with late-onset schizophrenia (Rajji and Mulsant, 2008; Rajji et al., 2009). Although early-onset and late-onset patients were found to have similar reductions in the volume of several brain areas, such as medial temporal regions, anterior superior temporal gyri (Barta et al., 1997), and mean corpus callosum (Sachdev and Brodaty, 1999), late-onset schizophrenic patients had larger thalamic volumes than early-onset patients (Corey-Bloom et al., 1995). These differences suggested the existence of structural and functional differences between early-onset and late-onset schizophrenia. Therefore, it is important to screen *FA* alterations in whole white matter only in homogenous schizophrenic patients with late-onset schizophrenia.

The Positive and Negative Syndrome Scale (PANSS) has been widely used for typological and dimensional assessment of schizophrenia. The negative symptoms identified using the PANSS share many characteristics with cognitive deficits and have been correlated with their severity in cross-sectional assessments of schizophrenia (Harvey et al., 2006). Our previous studies demonstrated that PANSS scores negatively correlated with decreased *FA* in the corpus callosum of chronic schizophrenic patients (Kong et al., 2011) and decreased *FA* in right anterior cingulum of early-onset schizophrenic patients (Tang et al., 2010). Significant negative correlations between clinical symptoms and decreased *FA* values were also observed in left uncinate, superior longitudinal fasciculus, and inferior frontal white matter in patients with schizophrenia (Wolkin et al., 2003; Skelly et al., 2008). However, the correlations of clinical symptoms, i.e., the PANSS score, with *FA* alterations in white matter of patients with late-onset schizophrenia have not been reported.

In this study we used a voxel-based DTI technique to investigate white matter abnormalities in patients with late-onset schizophrenia compared with age-, gender-, and education-matched healthy subjects. Cognitive functions were measured, and correlations of *FA* values with PANSS scores, cognitive test scores, age, medication dosages, and duration of illness were analyzed.

2. Methods

2.1. Subjects

Twenty late-onset inpatient schizophrenic patients (15 females, 5 males) with an average age of 46.9 years and average education of 8.4 years were recruited from December 2007 to November 2008 at the Institute of Mental Health of the Second Xiangya Hospital, Central South University. All participants met the following inclusion criteria: (1) fulfilled the DSM-IV-TR criteria for schizophrenia (Diagnostic and Statistical Manual of Mental Disorders, fourth edition, text

revision, American Psychiatric Association, 2000); (2) were free of concurrent psychiatric disorders; (3) had no comorbid Axis I diagnosis; (4) were aged 40 to 60 years; (5) had an age at onset of schizophrenia ≥ 40 years; (6) had no history of major neurological or physical disorders or substance abuse; (7) were right-handed; and (8) had a short duration of illness (< 10 years). Schizophrenia was diagnosed by clinical psychiatrists using the Structured Clinical Interview for DSM-IV-TR, patient version (SCID-I/P). Seventeen healthy subjects matched with the patients on age (40–58 years), gender (13 females, 4 males), and average education (8.2 years) were recruited by advertisement as a control group. Control subjects were confirmed to be (1) free of any known psychiatric condition; (2) without a history of major physical or neurological illness or substance abuse; (3) without a family history of psychosis in their first-degree relatives; and (4) right-handed. The study was approved by the Ethics Committee of Central of the Second Xiangya Hospital. Signed informed consent forms were obtained from all patients and healthy controls who participated in the study.

2.2. Positive and negative syndrome scale (PANSS)

Patients with a positive diagnosis of schizophrenia were evaluated with the PANSS interview and were then assessed on the PANSS scales (Kay et al., 1987). The assessments were conducted by clinical psychiatrists with intensive training in PANSS interviewing and rating methods.

2.3. Cognitive testing

A set of cognitive measurements was performed as follows: (1) Executive function/reasoning and problem solving were tested using the computerized 128-card version of the Wisconsin Card Sorting Test (WCST); (2) attention and immediate recall were tested using the Digit Span Subtest from the Wechsler Adult Intelligence Scale-Revised (WAIS-R) (Gong, 1989); and (3) Visual attention and task switching were tested using the Trail-making Test (Gaudino et al., 1995).

2.4. Imaging acquisition

Magnetic resonance imaging was performed on a 1.5 T General Electric MRI scanner. Foam pads were used to limit head motion and reduce scanner noise. Image sequences were acquired by the use of diffusion-weighted imaging with single-shot echo planar imaging (EPI) in alignment with the anterior–posterior commissure plane. The diffusion-sensitizing gradients were applied along 13 non-collinear directions ($b=1000$ s/mm²), together with an acquisition without diffusion weighting ($b=0$). Thirty contiguous axial slices were acquired with the following parameters: repetition time=12,000 ms; echo time=107 ms; acquisition matrix=128 × 128; field of view=24 × 24 cm; number of excitations=5; slice thickness=4 mm and no gap.

2.5. SPM-VBM analysis

The software DTI studio (version 2.40) was used to calculate diffusion-weighted images. The resulting *FA* images were transformed into Montreal Neurological Institute (MNI) standard space with statistical parametric mapping 5 (SPM5) (Wellcome Department of Cognitive Neurology, London, UK) according to previously described methods (Focke et al., 2008). Initially, a generic *FA* template was built from the control group by normalizing the extracted b_0 image to the SPM5 EPI template and applying this transformation information to the *FA* maps and reslicing to 2 mm cubic resolution. Afterwards, the normalized *FA* maps were averaged and smoothed with an 8-mm full width at half-maximum (FWHM) Gaussian kernel to form the *FA* template (Wang et al., 2008). All native *FA* maps (patients and controls) were then normalized to this template and resliced to 2-mm cubic resolution as well. All normalization steps were carried out with SPM default settings that encompassed affine registration (12 degrees of freedom) and 16 non-linear iterations using a discrete cosine basis function with a frequency cutoff of 25 (Ashburner and Friston, 1999).

Differences in *FA* between late-onset schizophrenia (LOS) patients and healthy subjects were analyzed by two samples *t*-test on a voxel-by-voxel basis with SPM5 software. Age was set as covariate of no interest. A white matter mask was used to restrict the search volume for analysis to mitigate multiple comparison corrections. This white matter mask was defined by binarizing the SPM5 a priori white matter template to a binary mask through thresholding of each voxel at 50% white matter to define white matter regions for analysis (Menzies et al., 2008). Clusters of 50 voxels or greater that survived a threshold of false discovery rate (FDR) corrected $p < 0.05$ were considered significant. For visualization of the regions showing significantly different *FA* values between the two groups, the significant clusters were superimposed onto SPM5's spatially normalized template brain.

In order to further investigate the clinical association of significant clusters, regions of interest (ROIs) were analyzed. MarsBar 0.41 (<<http://marsbar.sourceforge.net/>>) was used to extract ROIs containing all the voxels classified as white matter from spatially normalized and smoothed *FA* images. Mean *FA* values of the

ROIs were then calculated using `log_roi_batch v2.0` (<http://www.aimfeld.ch/>). A masking threshold for FA values of 0.18 was set up to exclude voxels containing partial volume of white matter. Finally, the averaged FA values of individual clusters were calculated for each subject. A two-sample *t*-test (SPSS 13.0, Chicago) was used to compare these FA values of the clusters between healthy subjects and patients. We used $p < 0.05$ as a statistical threshold. Correlation between FA values and clinical factors including duration of illness, chlorpromazine-equivalent medication dose, cognitive test scores and PANSS scores of significant clusters in LOS patients were analyzed using partial correlation analysis controlled for age (two-tailed $p < 0.05$).

2.6. TBSS analysis

Voxelwise statistical analysis of the FA data was carried out using TBSS (Tract-Based Spatial Statistics) (Smith et al., 2006) with part of FSL (Smith et al., 2004). First, FA images were created by fitting a tensor model to the raw diffusion data using FDT, and then brain-extracted using BET (Smith, 2002). All subjects' FA data were then aligned into a common space using the nonlinear registration tool FNIRT (Klein et al., 2009), which uses a *b*-spline representation of the registration warp field (Rueckert et al., 1999). Second, the mean FA image was created and thinned to create a mean FA skeleton, which represents the centers of all tracts common to the group. Each subject's aligned FA data were then projected onto this skeleton, and the resulting data were entered into voxelwise cross-subject statistics. The testing was performed by the FSL randomizing program, which uses 5000 random permutations (Nichols and Holmes, 2002). Age was entered into the analysis as a covariate to ensure that any observed difference of FA between groups was independent of age-related changes. A statistical threshold of $t > 2$, $p < 0.05$, corrected for multiple comparisons with Threshold-Free Cluster Enhancement (TFCE), was used for this analysis (Smith and Nichols, 2009).

3. Results

Table 1 presents the demographic and clinical data for the two groups. We included 20 patients with LOS (15 females, 5 males) with a mean age of 46.9 ± 5.0 years and an average education of 8.4 ± 3.3 years. All patients were diagnosed with the paranoid subtype of schizophrenia according to DSM-IV-TR. In the 17 healthy controls (13 females, 4 males), the mean age was 46.9 ± 5.0 years and the average education was 8.2 ± 2.9 years. All recruited patients had a short duration of illness (mean: 2.9 ± 2.6 years; range: 0.25–9 years) at entry into the study. All patients received typical or atypical antipsychotic medications and the mean chlorpromazine-equivalent dosage was 244.4 mg/day (S.D. 99.7 mg/day; range: 62.5–363.6 mg/day) at the time of scanning (perphenazine [$n=3$], sulpiride [$n=2$], risperidone [$n=9$], clozapine [$n=2$], or quetiapine [$n=4$]). Patients and control subjects were statistically similar in terms of gender composition, age, handedness, and educational level (Table 1).

Voxelwise analysis of white matter anisotropy showed a significant reduction in FA in left parietal lobe and right posterior cingulum in patients with LOS compared with healthy subjects (Fig. 1A, Table 2). TBSS analysis only showed a significant reduction in FA in the left parietal lobe (Fig. 1B). In contrast, no region showed a significant increase in FA in patients. ROI analyses confirmed a significant reduction in FA in the left parietal

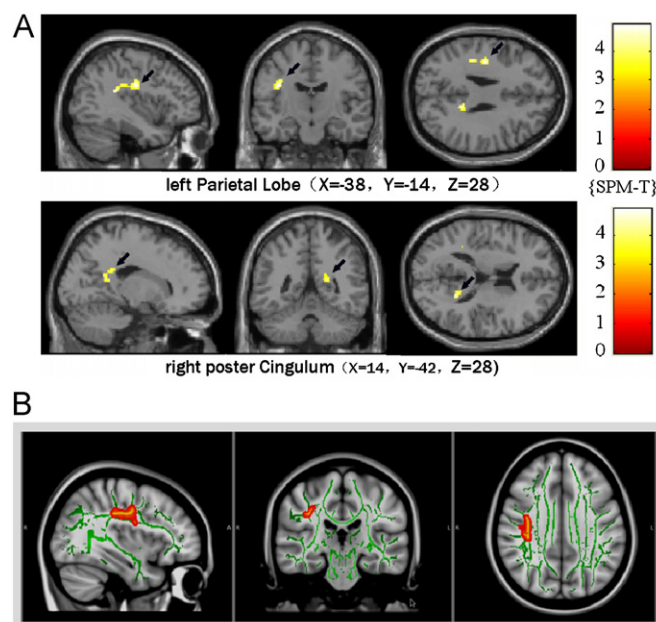


Fig. 1. Clusters with reduced FA value in late-onset schizophrenia compared with healthy controls. The position of sagittal and coronal MRI sections display significant differences between the LOS group and the control group. (A) Results from the SPM-VBM method. Black arrows indicate the significant area. (B) Results from the TBSS method.

Table 2

Clusters with reduced FA values in late-onset schizophrenia patients vs. healthy subjects (FDR corrected $p < 0.05$).

Cluster size	Peak Z value	MNI coordinate			Location
		x	y	z	
119	4.21	-38	-14	28	Left parietal lobe
91	3.97	14	-42	28	Right post cingulum

Coordinates are given for the maximally significant voxel in each area, where *x* defines the lateral placement from the midline (left=negative), *y* defines the anteroposterior displacement relative to the anterior commissure (posterior=negative), and *z* defines the vertical position relative to the anteroposterior commissural line (down=negative).

Table 1

Clinical characteristics.

	Patients with late-onset schizophrenia	Healthy subjects	<i>p</i> value
Male/female	5/15	4/13	–
Age (years)	46.9 ± 5.0 (range: 40–58)	47.4 ± 6.0 (range: 40–58)	0.328
Education (years)	8.4 ± 3.3 (range: 1–14)	8.2 ± 2.9 (range: 3–12)	0.689
Length of illness (years)	2.9 ± 2.6 (range: 0.25–9)	–	–
PANSS total score	61.8 ± 12.5 (range: 40–85)	–	–
PANSS positive	22.0 ± 7.1 (range: 12–34)	–	–
PANSS negative	12.2 ± 3.9 (range: 7–20)	–	–
Risperidone	9	–	–
Quetiapine	4	–	–
Clozapine	2	–	–
Perphenazine	2	–	–
Sulpiride	3	–	–
Chlorpromazine-equivalent dosage (mg/day)	244.4 ± 99.7 (range: 62.5–363.6)	–	–

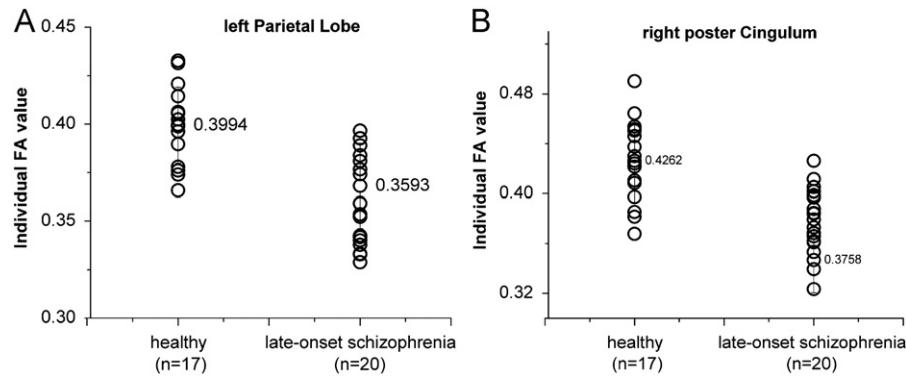


Fig. 2. Regional FA value of each subject in healthy and late-onset schizophrenia groups. (A) Scatterplot of FA values in the left parietal lobe. (B) Scatterplot of FA values in right poster cingulum.

Table 3
Cognition tests.

Tests	Patients with late-onset schizophrenia	Healthy subjects	<i>p</i> value
WCST			
Categories completed	4.25 ± 1.25	5.29 ± 0.92	0.007
Total WCST number	123.35 ± 10.65	117.24 ± 14.68	0.152
False response	77.85 ± 19.64	61.94 ± 19.51	0.019
Perseverative errors	59.2 ± 22.78	42.94 ± 19.39	0.027
WAIS-R-Digit span			
Forward	6.95 ± 1.5	8 ± 1.41	0.036
Backward	3.6 ± 1.43	5.06 ± 1.56	0.005
Total scores	10.55 ± 2.5	13.06 ± 1.85	0.002
Trial-marking test			
Form A	72.05 ± 34.5	58.82 ± 21.22	0.178
Form B	203.20 ± 99.85	145.18 ± 65.95	0.048

lobe and the right poster cingulum in patients with LOS compared with healthy subjects (Fig. 2). A narrow range of PANSS scores was seen in the LOS patients, showing no significant difference from healthy controls. Even without correction for multiple comparisons (i.e., Bonferroni correction), there were no significant correlations between decreased FA and PANSS positive subscale scores, PANSS negative subscale scores, PANSS total scores, cognitive test scores, age, antipsychotic medication dosages, and duration of psychosis ($p > 0.05$). Also, when age was set as a controlling factor in the correlation analysis, no differences were found between decreased FA of the significant clusters and clinical variables.

As shown in Table 3, the late-onset schizophrenic patients completed significantly fewer categories and showed significantly more incorrect responses and perseverative errors on the WCST compared with healthy subjects ($p < 0.01$, $p < 0.05$, $p < 0.05$, respectively). In the WAIS-R Digit Span Subtest, patients remembered significantly fewer numbers in both the forward and backward phases compared with healthy subjects ($p < 0.05$, $p < 0.01$, respectively). In the Trial-Making Test, patients required a significantly longer time to finish form B compared with healthy subjects ($p < 0.05$). These outcomes suggest cognitive deficits in executive function/reasoning, problem solving, task switching, attention, and immediate recall in LOS patients.

4. Discussion

In this study we first evaluated whole white matter integrity in patients with LOS using DTI. A significant reduction in fractional anisotropy (FA) was observed in the left parietal lobe and the right poster cingulum by voxel-based morphometry (VBM). In contrast, a significant reduction in FA was only observed in the left parietal lobe with the tract-based spatial statistics (TBSS) approach. VBM has some limitations in registration, smoothing, and sensitivity when it is used to analyze diffusion abnormality (Afzali et al.,

2011). Conversely, TBSS yields more sensitive and objective outcomes than VBM. Therefore, the combination of TBSS and VBM provided more reliable information. Contrary to reports in patients with early-onset and chronic schizophrenia, no correlation was found between FA and PANSS scores in LOS patients. Reduced FA may indicate impaired myelination, altered fiber organization, or aberrant axon morphology in white matter and fiber tracts. Therefore, the present study suggested that disruption of white matter integrity may be involved in the pathophysiology of LOS, but provided no evidence for its involvement in the etiology of LOS.

Deficits in cognitive functions and impairments in executive functions, learning, and verbal ability were previously observed in late-onset schizophrenia (Goldman-Rakic, 1994). Consistent with earlier findings, our study demonstrated that patients with LOS had significant deficits in cognitive functions (Table 3). In contrast to the findings in chronic schizophrenia (Kong et al., 2011) and early-onset schizophrenia (Tang et al., 2010), no significantly higher levels of positive and negative symptoms were observed in LOS patients (Table 1). A previous study demonstrated that patients with early-onset schizophrenia have greater cognitive deficits and more negative symptoms compared with LOS patients (Wetherell and Jeste, 2004). Therefore, differences in cognition and symptoms may suggest functional differences of the brain between early-onset and late-onset patients.

Most studies indicate that learning and memory are based on the integrity of temporal and frontal lobe areas. Structural abnormalities of fronto-temporal connectivity may constitute a basis for the impairment of cognitive functions, such as selective attention, language processing, and working memory. These findings suggest that structural abnormalities in fronto-temporal connectivity, temporal and frontal lobe areas may contribute to the cognitive impairment in LOS patients. However, previous studies demonstrated conflicting findings concerning the relationship between structural abnormalities and psychotic symptoms. For example, prefrontal white matter anisotropy was revealed to correlate with negative symptoms, impulsiveness, and aggressiveness in schizophrenia (Hoptman et al., 2002; Wolkin et al., 2003). In contrast, other studies revealed no relationship between DTI indices and psychiatric symptoms (Rowland et al., 2009). In this study, reduced FA in the left frontal and bilateral temporal regions exhibited no correlation with PANSS positive or negative symptom scores or with cognitive deficits in LOS. This may indicate that the relationship between white matter alterations and PANSS symptoms is more complicated than a linear pattern. But it may also suggest that (1) white matter abnormality is not the etiology of LOS or that DTI alterations are not specific indicators of LOS; and (2) the heterogeneity of patients may be a factor contributing to the conflicting findings.

Aging has been found to be related to white matter integrity in both healthy populations (Bennett et al., 2010) and schizophrenic patients (Pfefferbaum et al., 2000). Rosenberger et al. (2008) found an age-associated *FA* reduction in frontal–temporal connectivity in schizophrenia. Some studies even reported inverse correlations between anisotropy measurements and duration of illness (Shin et al., 2006). Our findings of decreased *FA* in white matter in LOS patients (age 40–60) are also inconsistent with previous findings in very-late-onset schizophrenia (after age of 60) (Jones et al., 2005). This appears to reflect the aging difference. However, no differences were found between *FA* values of the significant clusters and clinical variables in this study regardless of whether age was set as a controlling factor in the correlation analysis. Also, antipsychotic medication can affect white matter integrity. For example, Minami et al. (2003) reported a positive correlation of left frontal *FA* with antipsychotic medication dose. Kuroki et al. (2006) reported an inverse correlation between anisotropy measurements and antipsychotic dose. Interestingly, in this study no significant correlation was found between reduced *FA* values and antipsychotic medication dosages in LOS patients. These negative results might reflect the advantage of homogenous patients in our study. The relatively narrow onset age range from 40 to 60 years has the advantage of minimizing the effects of onset age and diagnostic heterogeneity, while comparison with age-matched controls also minimized the effect of aging. However, the result of no correlations might also be bias due to a relatively small sample size.

In chronic schizophrenia, most of the consistent findings in the reduction of *FA* were identified in the frontal lobe (Schlösser et al., 2007; Seok et al., 2007), corpus callosum (Caan et al., 2006), and the cingulate. In addition, multiple white matter tracts that provide for intralobar and interlobar transfer of neural signals have shown lower *FA* in patients with chronic schizophrenia. Especially, evaluation of fronto–temporal connections (Rosenberger et al., 2008), such as the uncinate fasciculus (Caan et al., 2006), cingulum bundle (Nestor et al., 2007), arcuate fasciculus, and fornix (Takei et al., 2008), exhibited more consistent findings in chronic schizophrenia. Patients with first-episode and early-onset schizophrenia share many commonalities, which include being early in the course of their illness, being relatively young, and not having been through long-term treatment with medication, and they tend to display a similar amount of heterogeneity. Indeed, decreases in *FA* in first-episode and early-onset schizophrenia have been found in many regions, including the anterior cingulate (Hao et al., 2006), frontal lobe (Szeszko et al., 2008), parietal lobe (Hao et al., 2006), cerebellar peduncle (Kyriakopoulos et al., 2008), hippocampus (White et al., 2007), and perihippocampal gyrus (Hao et al., 2006). In our study LOS patients showed significant reductions in *FA* in white matter integrity in the frontal and bilateral temporal regions, findings that are consistent with findings in earlier onset schizophrenia (Kubicki et al., 2007). This suggests that frontal and temporal white matter seems to be the most commonly affected areas in various types of patients with schizophrenia including chronic patients, first-episode patients, early-onset patients, and late-onset patients, but are not the the specific areas most affected in LOS. We propose that the white matter tracts connecting frontal and temporal area might be unrelated to age, duration of illness, medication exposure, or the presence of psychotic symptoms of LOS.

We acknowledge that our study has the following limitations: (1) The sample size, although comparable with most DTI studies to date, was relatively small. Therefore, it cannot be completely ruled out that the lack of correlation between decreased *FA* and clinical symptoms in LOS might be spurious. However, a narrow range of PANSS scores was seen in this study. This may reflect the

homogeneity of LOS patients and suggests a good representation of the current samples in LOS patients. (2) DTI abnormalities in white matter have been previously reported in first-episode, early-onset, and chronic schizophrenia. Although *FA* data from these studies could be used as reference for our *FA* changes, no doubt, it will provide more promising information if early- and late-onset as well as chronic schizophrenia are studied in parallel. The voxel-averaged values of DTI could be affected by multiple factors, such as possible contamination of gray matter and the variability of location, shape, and size of fiber tracts. (3) All patients with diagnosis of late-onset schizophrenia in our study received antipsychotic medication that could have affected white matter integrity (Peters et al., 2010). However, no correlation between reduced *FA* and antipsychotic medication dosage was observed. Therefore, we excluded a relevant confounding effect of medication on our results. However, the yearly dose is a more important factor than the daily dose adopted in this study. Generally, an accurate dose could only be obtained from a well-controlled trial because many outpatients are non-compliant, to varying degrees, in taking medication. Additional studies using drug-naïve patients in a first episode of schizophrenia would be desirable. (4) The limitation of *FA* has been increasingly recognized by researchers as they have turned to other indices such as axial and radial diffusivities to elucidate the nature of white matter abnormalities in schizophrenia (Chan et al., 2010). (5) A slice thickness of 4 mm and only 13 directions obtained is also a limitation of the study. (6) Finally, this study only analyzed *FA* parameters without parallel analyses of volumetric changes. Despite these limitations, the current study found significantly reduced *FA* in white matter in patients with late-onset schizophrenia. Although comparable *FA* reductions have been identified in first-episode, early-onset, and chronic schizophrenia, the late-onset subgroup is relatively rare, and previous no study has examined changes in *FA* of late-onset schizophrenia. Thus, our study provides information that fills a gap in our knowledge of *FA* effects across the whole range of schizophrenia.

In conclusion, abnormal white matter integrity in the frontal and temporal area was found in late-onset schizophrenia. It remains uncertain whether specific regions of white matter might emerge as particularly important for the pathophysiology of late-onset schizophrenia. Forthcoming studies with larger, drug-naïve, and more homogeneous patient groups may realize the true potential of diffusion tensor imaging.

Financial disclosure

The authors declare no conflict of interest.

Authors' contribution

Liping Chen was responsible for sample recruitment, data acquisition, data analysis, interpreting the results and preparing the manuscript.

Weiqing Liu was responsible for sample recruitment, data acquisition, data analysis and interpretation.

Qifeng Wang was responsible for sample recruitment, data acquisition and data analysis.

Tianzi Jiang was responsible for data acquisition, data analysis and interpreting the findings.

Jicai Wang was responsible for data acquisition, data analysis, interpreting the findings and for critically revising the manuscript.

Xiuyan Wang was responsible for the sample recruitment and data analysis.

Bing Zhou was responsible for the sample recruitment and data analysis.

Jinsong Tang was responsible for the study design, data analysis, interpretation of findings, manuscript preparation and providing funding support.

Xiaogang Chen was responsible for the study concept, design, analysis, interpretation of findings, critically revising the manuscript and providing funding support.

Acknowledgments

This study was supported by the Natural Science Foundation of China (Grant No. 30900486, 81100996, 81130020), the National Key Basic Research and Development Program (973) (Grant No. 2012CB517904), National Key Technology R&D Program in the 12th Five-Year Plan of China (2012BAI01B07), Central Colleges Basic Scientific Research Operating Expenses (2011QNZT170), and Specialized Research Fund for the Doctoral Program of Higher Education (20110162120013). However, the funders had no role in study design, data collection and analysis, decision to publish, or preparation of the manuscript.

References

- Afzali, M., Soltanian-Zadeh, H., Elisevich, K.V., 2011. Tract based spatial statistical analysis and voxel based morphometry of diffusion indices in temporal lobe epilepsy. *Computers in Biology and Medicine* 41, 1082–1091.
- Ashburner, J., Friston, K.J., 1999. Nonlinear spatial normalization using basis functions. *Human Brain Mapping* 7, 254–266.
- Barta, P.E., Powers, R.E., Aylward, E.H., Chase, G.A., Harris, G.J., Rabins, P.V., Tune, L.E., Pearlson, G.D., 1997. Quantitative MRI volume changes in late onset schizophrenia and Alzheimer's disease compared to normal controls. *Psychiatry Research: Neuroimaging* 68, 65–75.
- Basser, P.J., 1995. Inferring microstructural features and the physiological state of tissues from diffusion-weighted images. *NMR in Biomedicine* 8, 333–344.
- Beaulieu, C., 2002. The basis of anisotropic water diffusion in the nervous system—a technical review. *NMR in Biomedicine* 15, 435–455.
- Bennett, I.J., Madden, D.J., Vaidya, C.J., Howard, D.V., Howard Jr., J.H., 2010. Age-related differences in multiple measures of white matter integrity: a diffusion tensor imaging study of healthy aging. *Human Brain Mapping* 31, 378–390.
- Caan, M.W., Vermeer, K.A., van Vliet, L.J., Majoie, C.B., Peters, B.D., den Heeten, G.J., Vos, F.M., 2006. Shaving diffusion tensor images in discriminant analysis: a study into schizophrenia. *Medical Image Analysis* 10, 841–849.
- Chan, W.Y., Yang, G.L., Chia, M.Y., Lau, I.Y., Sitoh, Y.Y., Nowinski, W.L., Sim, K., 2010. White matter abnormalities in first-episode schizophrenia: a combined structural MRI and DTI study. *Schizophrenia Research* 119, 52–60.
- Corey-Bloom, J., Jernigan, T., Archibald, S., Harris, M.J., Jeste, D.V., 1995. Quantitative magnetic resonance imaging of the brain in late-life schizophrenia. *American Journal of Psychiatry* 152, 447–449.
- Focke, N.K., Yogarajah, M., Bonelli, S.B., Bartlett, P.A., Symms, M.R., Duncan, J.S., 2008. Voxel-based diffusion tensor imaging in patients with mesial temporal lobe epilepsy and hippocampal sclerosis. *Neuroimage* 40, 728–737.
- Friedman, J.L., Tang, C., Carpenter, D., Buchsbaum, M., Schmeidler, J., Flanagan, L., Golemb, S., Kanellopoulou, I., Ng, J., Hof, P.R., Harvey, P.D., Tsopelas, N.D., Stewart, D., Davis, K.L., 2008. Diffusion tensor imaging findings in first-episode and chronic schizophrenia patients. *American Journal of Psychiatry* 165, 1024–1032.
- Gaudino, E.A., Geisler, M.W., Squires, N.K., 1995. Construct validity in the trail making test: what makes Part B harder? *Journal of Clinical and Experimental Neuropsychology* 17, 529–535.
- Goldman-Rakic, P., 1994. Working memory dysfunction in schizophrenia. *Journal of Neuropsychiatry & Clinical Neurosciences* 6, 348–357.
- Gong, Y., 1989. Wechsler Memory Scale-Revised in China. Mapping Press, Changsha, Hunan, China.
- Hao, Y., Liu, Z., Jiang, T., Gong, G., Liu, H., Tan, L., Kuang, F., Xu, L., Yi, Y., Zhang, Z., 2006. White matter integrity of the whole brain is disrupted in first-episode schizophrenia. *Neuroreport* 17, 23–26.
- Harvey, P.D., Green, M.F., Bowie, C., Loeber, A., 2006. The dimensions of clinical and cognitive change in schizophrenia: evidence for independence of improvements. *Psychopharmacology (Berl)* 187, 356–363.
- Hoptman, M.J., Johnson, G., Weiss, E., Bilder, R.M., Lim, K.O., 2002. Frontal white matter microstructure, aggression, and impulsivity in men with schizophrenia: a preliminary study. *Biological Psychiatry* 52, 9–14.
- Howard, R., Rabins, P.V., Seeman, M.V., Jeste, D.V., 2000. Late-onset schizophrenia and very-late-onset schizophrenia-like psychosis: an international consensus. The International Late-Onset Schizophrenia Group. *American Journal of Psychiatry* 157, 172–178.
- Jones, D.K., Catani, M., Pierpaoli, C., Reeves, S.J., Shergill, S.S., O'Sullivan, M., Maguire, P., Horsfield, M.A., Simmons, A., Williams, S.C., Howard, R.J., 2005. A diffusion tensor magnetic resonance imaging study of frontal cortex connections in very-late-onset schizophrenia-like psychosis. *American Journal of Geriatric Psychiatry* 13, 1092–1099.
- Kay, S.R., Fiszbein, A., Opler, L.A., 1987. The positive and negative syndrome scale (PANSS) for schizophrenia. *Schizophrenia Bulletin* 13, 261–276.
- Klein, A., Andersson, J., Ardekani, B.A., Ashburner, J., Avants, B., Chiang, M.C., Christensen, G.E., Collins, D.L., Gee, J., Hellier, P., Song, J.H., Jenkinson, M., Lepage, C., Rueckert, D., Thompson, P., Vercauteren, T., Woods, R.P., Mann, J.J., Parsey, R.V., 2009. Evaluation of 14 nonlinear deformation algorithms applied to human brain MRI registration. *Neuroimage* 46, 786–802.
- Kong, X., Ouyang, X., Tao, H., Liu, H., Li, L., Zhao, J., Xue, Z., Wang, F., Jiang, S., Shan, B., Liu, Z., 2011. Complementary diffusion tensor imaging study of the corpus callosum in patients with first-episode and chronic schizophrenia. *Journal of Psychiatry and Neuroscience* 36, 120–125.
- Kubicki, M., McCarley, R., Westin, C.F., Park, H.J., Maier, S., Kikinis, R., Jolesz, F.A., Shenton, M.E., 2007. A review of diffusion tensor imaging studies in schizophrenia. *Journal of Psychiatric Research* 41, 15–30.
- Kuroki, N., Kubicki, M., Nestor, P.G., Salisbury, P.G., Park, H.J., Levitt, J.J., Woolston, S., Frumin, M., Niznikiewicz, M., Westin, C.F., Maier, S.E., McCarley, R.W., Shenton, M.E., 2006. Fornix integrity and hippocampal volume in male schizophrenic patients. *Biological Psychiatry* 60, 22–31.
- Kyriakopoulos, M., Vyas, N.S., Barker, G.J., Chitnis, X.A., Frangou, S., 2008. A diffusion tensor imaging study of white matter in early-onset schizophrenia. *Biological Psychiatry* 63, 519–523.
- Menzies, L., chamberlain, S.R., laird, A.R., Thelen, S.M., Sahakian, B.J., Bullmore, E.T., 2008. Integrating evidence from neuroimaging and neuropsychological studies of obsessive-compulsive disorder: the orbitofronto-striatal model revisited. *Neuroscience & Biobehavioral Reviews* 32, 525–549.
- Minami, T., Nobuhara, K., Okugawa, G., Takase, K., Yoshida, T., Sawada, S., Haka, S., Ikeda, K., Kinoshita, T., 2003. Diffusion tensor magnetic resonance imaging of disruption of regional white matter in schizophrenia. *Neuropsychobiology* 47, 141–145.
- Nichols, T.E., Holmes, A.P., 2002. Nonparametric permutation tests for functional neuroimaging: a primer with examples. *Human Brain Mapping* 15, 1–25.
- Nestor, P.G., Kubicki, M., Spencer, K.M., Niznikiewicz, M., McCarley, R.W., Shenton, M.E., 2007. Attentional networks and cingulum bundle in chronic schizophrenia. *Schizophrenia Research* 90, 308–315.
- Pantelis, C., Yücel, M., Wood, S.J., Velakoulis, D., Sun, D., Berger, G., Stuart, G.W., Yung, A., Phillips, L., McGorry, P.D., 2005. Structural brain imaging evidence for multiple pathological processes at different stages of brain development in schizophrenia. *Schizophrenia Bulletin* 31, 672–696.
- Peters, B.D., Blas, J., de Haan, L., 2010. Diffusion tensor imaging in the early phase of schizophrenia: what have we learned? *Journal of Psychiatric Research* 44, 993–1004.
- Pfefferbaum, A., Sullivan, E.V., Hedehus, M., Lim, K.O., Adalsteinsson, E., Moseley, M., 2000. Age-related decline in brain white matter anisotropy measured with spatially corrected echo-planar diffusion tensor imaging. *Magnetic Resonance in Medicine* 44, 259–268.
- Rajji, T.K., Ismail, Z., Mulsant, B.H., 2009. Age at onset and cognition in schizophrenia: meta-analysis. *British Journal of Psychiatry* 195, 286–293.
- Rajji, T.K., Mulsant, B.H., 2008. Nature and course of cognitive function in late-life schizophrenia: a systematic review. *Schizophrenia Research* 102, 122–140.
- Rosenberger, G., Kubicki, M., Nestor, P.G., Connor, E., Bushnell, G.B., Markant, D., Niznikiewicz, M., Westin, C.F., Kikinis, R., Saykin, A., McCarley, R.W., Shenton, M.E., 2008. Age-related deficits in fronto-temporal connections in schizophrenia: a diffusion tensor imaging study. *Schizophrenia Research* 102, 181–188.
- Rueckert, D., Sonoda, L.I., Hayes, C., Hill, D.L., Leach, M.O., Hawkes, D.J., 1999. Nonrigid registration using free-form deformations: application to breast MR images. *IEEE Transactions on Medical Imaging* 18, 712–721.
- Rowland, L.M., Spieker, E.A., Francis, A., Barker, P.B., Carpenter, W.T., Buchanan, R.W., 2009. White matter alterations in deficit schizophrenia. *Neuropsychopharmacology* 34, 1514–1522.
- Sachdev, P., Brodaty, H., 1999. Quantitative study of signal hyperintensities on T2-weighted magnetic resonance imaging in late-onset schizophrenia. *American Journal of Psychiatry* 156, 1958–1967.
- Schlösser, R.G., Nenadic, I., Wagner, G., Güllmar, D., von Consbruch, K., Köhler, S., Schultz, C.C., Koch, K., Fitzek, C., Matthews, P.M., Reichenbach, J.R., Sauer, H., 2007. White matter abnormalities and brain activation in schizophrenia: a combined DTI and fMRI study. *Schizophrenia Research* 89, 1–11.
- Seok, J.H., Park, H.J., Chun, J.W., Lee, S.K., Cho, H.S., Kwon, J.S., Kim, J.J., 2007. White matter abnormalities associated with auditory hallucinations in schizophrenia: a combined study of voxel-based analyses of diffusion tensor imaging and structural magnetic resonance imaging. *Psychiatry Research: Neuroimaging* 156, 93–104.
- Shin, Y.W., Kwon, J.S., Ha, T.H., Park, H.J., Kim, D.J., Hong, S.B., Moon, W.J., Lee, J.M., Kim, I.Y., Kim, S.I., Chung, E.C., 2006. Increased water diffusivity in the frontal and temporal cortices of schizophrenic patients. *Neuroimage* 30, 1285–1291.
- Skelly, L.R., Calhoun, V., Meda, S.A., Kim, J., Mathalon, D.H., Pearlson, G.D., 2008. Diffusion tensor imaging in schizophrenia: relationship to symptoms. *Schizophrenia Research* 98, 157–162.
- Smith, S.M., 2002. Fast robust automated brain extraction. *Human Brain Mapping* 17, 143–155.
- Smith, S.M., Jenkinson, M., Woolrich, M.W., Beckmann, C.F., Behrens, T.E., Johansen-Berg, H., Bannister, P.R., De Luca, M., Drobnjak, I., Flitney, D.E., Niaz, R.K.,

- Saunders, K.O., Vickers, J., Zhang, Y., De Stefano, N., Brady, J.M., Matthews, P.M., 2004. Advances in functional and structural MR image analysis and implementation as FSL. *Neuroimage* 23, S208–219.
- Smith, S.M., Jenkinson, M., Johansen-Berg, H., Rueckert, D., Nichols, T.E., Mackay, C.E., Watkins, K.E., Ciccarelli, O., Cader, M.Z., Matthews, P.M., Behrens, T.E., 2006. Tract-based spatial statistics: voxelwise analysis of multi-subject diffusion data. *Neuroimage* 31, 1487–1505.
- Smith, S.M., Nichols, T.E., 2009. Threshold-free cluster enhancement: addressing problems of smoothing, threshold dependence and localisation in cluster inference. *Neuroimage* 44, 83–98.
- Szeszko, P.R., Robinson, D.G., Ashtari, M., Vogel, J., Betensky, J., Sevy, S., Ardekani, B.A., Lencz, T., Malhotra, A.K., McCormack, J., Miller, R., Lim, K.O., Gunduz-Bruce, H., Kane, J.M., Bilder, R.M., 2008. Clinical and neuropsychological correlates of white matter abnormalities in recent onset schizophrenia. *Neuropsychopharmacology* 33, 976–984.
- Takei, K., Yamasue, H., Abe, O., Yamada, H., Inoue, H., Suga, M., Sekita, K., Sasaki, H., Rogers, M., Aoki, S., Kasai, K., 2008. Disrupted integrity of the fornix is associated with impaired memory organization in schizophrenia. *Schizophrenia Research* 103, 52–61.
- Tang, J., Liao, Y., Zhou, B., Tan, C., Liu, T., Hao, W., Hu, D., Chen, X., 2010. Abnormal anterior cingulum integrity in first episode, early-onset schizophrenia: a diffusion tensor imaging study. *Brain Research* 1343, 199–205.
- Wang, F., Kalmar, J.H., Edmiston, E., Chepenik, L.G., Bhagwagar, Z., Spencer, L., Pittman, B., Jackowski, M., Papademetris, X., Constable, R.T., Blumberg, H.P., 2008. Abnormal corpus callosum integrity in bipolar disorder: a diffusion tensor imaging study. *Biological Psychiatry* 64, 730–733.
- Wetherell, J.L., Jeste, D.V., 2004. Older adults with schizophrenia. *Elder Care* 3, 8–11.
- White, T., Kendi, A.T., Lehericy, S., Kendi, M., Karatekin, C., Guimaraes, A., Davenport, N., Schulz, S.C., Lim, K.O., 2007. Disruption of hippocampal connectivity in children and adolescents with schizophrenia—a voxel-based diffusion tensor imaging study. *Schizophrenia Research* 90, 302–307.
- White, T., Magnotta, V.A., Bockholt, H.J., Williams, S., Wallace, S., Ehrlich, S., Mueller, B.A., Ho, B.C., Jung, R.E., Clark, V.P., Lauriello, J., Bustillo, J.R., Schulz, S.C., Gollub, R.L., Andreasen, N.C., Calhoun, V.D., Lim, K.O., 2011. Global white matter abnormalities in schizophrenia: a multisite diffusion tensor imaging study. *Schizophrenia Bulletin* 37, 222–232.
- Wolkin, A., Choi, S.J., Szilagyi, S., Sanfilippo, M., Rotrosen, J.P., Lim, K.O., 2003. Inferior frontal white matter anisotropy and negative symptoms of schizophrenia: a diffusion tensor imaging study. *American Journal of Psychiatry* 160, 572–574.