

# Decreased regional homogeneity in schizophrenia: a resting state functional magnetic resonance imaging study

Haihong Liu<sup>a</sup>, Zhening Liu<sup>a</sup>, Meng Liang<sup>c</sup>, Yihui Hao<sup>a</sup>, Lihua Tan<sup>b</sup>, Fan Kuang<sup>b</sup>, Yanhong Yi<sup>a</sup>, Lin Xu<sup>a,d</sup> and Tianzi Jiang<sup>c</sup>

<sup>a</sup>Institute of Mental Health, <sup>b</sup>Department of Radiology, Second Xiangya Hospital, Central South University, Changsha, Hunan, <sup>c</sup>National Laboratory of Pattern Recognition, Institute of Automation, Chinese Academy of Sciences, Beijing and <sup>d</sup>Laboratory of Learning and Memory, Kunming Institute of Zoology, Chinese Academy of Sciences, Kunming, Yunnan, China

Correspondence and requests for reprints to Zhening Liu, Institute of Mental Health, Second Xiangya Hospital, Central South University, Changsha 410011, Hunan, China

Tel: + 86 13508489006; fax: + 0731 5554052; e-mail: zheningliu@yahoo.com.cn and Professor Tianzi Jiang, tel: + 86 1082614469; fax: + 86 1062551993; email: jiangtz@nlpr.ia.ac.cn

Sponsorship: The 973 Program of China (2006CB500800) supported this work.

Received 17 October 2005; accepted 10 November 2005

We used a newly reported regional homogeneity approach to measure the temporal homogeneity of blood oxygen level-dependent signal for exploring the brain activity of schizophrenia in a resting state. The results showed decreased regional homogeneity in schizophrenia, which distributed over the bilateral frontal, temporal, occipital, cerebellar posterior, right parietal and left limbic lobes, similar to the findings reported in previous resting state

functional studies. The brain regions that showed decreased regional homogeneity are believed to be involved in the psychopathology and pathophysiology of schizophrenia. Our results indicate that abnormal brain activity of schizophrenia may exist in a resting state and the regional homogeneity may be potentially helpful in understanding the resting state of schizophrenia. *NeuroReport* 17:19–22 © 2006 Lippincott Williams & Wilkins.

**Keywords:** functional magnetic resonance imaging, regional homogeneity, resting state, schizophrenia

## Introduction

Schizophrenia is a disastrous illness that affects approximately 1% of the whole population. Affected individuals frequently come to clinical attention during late adolescence or early adulthood. Most schizophrenic patients experience a lifetime of disability and about 10% will eventually commit suicide. The pathogenesis of schizophrenia, however, remains unclear. It is hoped that functional magnetic resonance imaging (fMRI) will allow new insight into the pathophysiology of schizophrenia. Task-related fMRI studies have been widely carried out on schizophrenia, but the required tasks are not easy to perform especially for patients.

Resting state fMRI, however, has attracted more attention recently because study participants are instructed simply to remain motionless and keep their eyes closed during the fMRI scan [1–3]. Therefore, resting state fMRI has the practical advantage of clinical application. Abnormal brain activity in the resting state of schizophrenia has been reported in numerous studies of electroencephalography (EEG) [4], positron-emission tomography (PET) [5] and single photon emission computed tomography (SPECT) [6,7]. None, however, has ever detected the brain activity of schizophrenia by using resting state fMRI.

In the present resting state fMRI study, a newly reported regional homogeneity (ReHo) method [3] was used to analyze the blood oxygen level-dependent (BOLD) signal of the brain. The ReHo is based on previous reports that fMRI activity is more likely to occur in clusters of several spatially contiguous voxels than in a single voxel [8,9]. Therefore, ReHo assumes that a given voxel is temporally similar to those of its neighbors. Kendall's coefficient of concordance (KCC) [10] was used to measure the similarity of the time series of this voxel with those of its nearest neighbors in a voxel-wise way. Then, the KCC value was given to this voxel and individual KCC maps were obtained. Different ReHo of brain activity between schizophrenic patients and controls was explored by using second-level statistical analysis on individual KCC maps. Here, we reported that decreased ReHo was found in schizophrenic patients by resting state fMRI study.

## Methods

### Participants

We recruited 18 normal controls (nine men, nine women, aged 19–33 years, mean age=24.44 years, SD=3.884; mean education level=15.28 years, SD=2.191), and 18 patients

with schizophrenia (nine men, nine women, aged 19–40 years, mean age=23.67 years, SD=4.379; mean education level=14.11 years, SD=1.676) diagnosed with DSM-IV (Diagnostic and Statistical Manual of Mental Disorders, fourth edition, American Psychiatric Publishing Inc., 1994) criteria. All schizophrenic patients were recruited from a pool of newly admitted patients at the Department of Psychiatry, Second Xiangya Hospital of Central South University, between March 2005 and July 2005. All participants met the following criteria: (1) right-handedness, (2) age between 18 and 45 years, (3) no history of neurological illness or other serious physical disease, (4) no history of alcohol or drug dependence, (5) no history of electroconvulsive therapy, (6) no presence of medication in 6 h before fMRI scan, (7) an ability and desire to cooperate with our experimental procedures and (8) written informed consent. Additionally, the controls had no personal or family history of psychotic disorder. Length of illness of the schizophrenic patients was  $26.83 \pm 19.20$  months. PANSS (Positive and Negative Symptom Scale) score was  $80.39 \pm 18.699$ . The two groups showed no differences in age, sex and years of education ( $P > 0.05$ ). The study was approved ethically by the Second Xiangya Hospital, Central South University.

### Resting state

Resting state was defined as no prescribed cognitive tasks during an fMRI scan. Participants were instructed simply to remain motionless, to keep their eyes closed and not think of anything in particular [1–3].

### Image acquisition

Images were acquired on a GE Signa 1.5 T scanner (General Electric, Fairfield, Connecticut, USA) equipped with high-speed gradients. The participant's head was positioned within a prototype quadrature birdcage head coil specifically developed for functional imaging of the brain. Foam padding was provided to minimize head movement. The following parameters were used for T1 anatomical imaging axially: 1924/7.5 ms (TR/TE), 20 slices,  $256 \times 256$  matrix,  $90^\circ$  flip angle, 24 cm field of view (FOV), 5 mm section thickness and 1 mm gap. At the same locations to anatomical slices, functional images were acquired by using an echoplanar imaging sequence with the following parameters: 2000/40 ms (TR/TE), 20 slices,  $64 \times 64$  matrix,  $90^\circ$  flip angle, 24 cm FOV, 5 mm section thickness and 1 mm gap. The fMRI scanning lasted for 6 min, so 180 time points were obtained. In addition, a three-dimensional spoiled gradient-recalled whole-brain volume was acquired sagittally with the following parameters: 12.1/4.2 ms (TR/TE),  $15^\circ$  flip angle,  $1.27 \times 1.27 \times 1.3$  mm spatial resolution, 172 slices, 24 cm FOV, NEX=2, 1.8 mm section thickness and no gap.

### Image preprocessing

Image preprocessing was conducted by using statistical parametric mapping (SPM2, Wellcome Department of Imaging Neuroscience, London, UK). The first 10 volumes of each functional time series were discarded because of instability of initial magnetic resonance imaging signal and adaptation of participants to the circumstance, leaving 170 volumes. The remaining fMRI images were corrected for the acquisition delay between slices and for the head motion. Motion time courses were obtained by estimating the values

for translation (mm) and rotation (degrees) for each participant. All participants had less than 1.5 mm maximum displacement in  $x$ ,  $y$ , or  $z$  and  $1.0^\circ$  of angular motion during the whole fMRI scan. The two-sample  $t$ -test showed no significant differences in total translation ( $P=0.69$ ) and rotation ( $P=0.36$ ) between the two groups. After slice acquisition correction and head motion correction, the fMRI was normalized to the standard SPM2 echoplanar imaging template, re-sampled to 3-mm cubic voxels, and then spatially smoothed with a Gaussian kernel of  $4 \times 4 \times 4$  mm<sup>3</sup> full-width at half-maximum. The resulting fMRI data were temporally band-pass filtered ( $0.01 < f < 0.08$  Hz) to reduce the low-frequency drift and physiological high-frequency respiratory and cardiac noise [1] for further ReHo analysis. For result visualization, the individual high-resolution three-dimensional anatomical image was also normalized to the standard SPM2 template. Averaging all individual normalized anatomical images generated the mean normalized anatomical image across participants. The voxels outside the mean brain were excluded to create a mask. Only the voxels within the mask were included in further analysis.

### Regional homogeneity analysis

ReHo analysis [3] was performed for each participant by calculating KCC of the time series of a given voxel with those of its nearest neighbors (26 voxels) on a voxel-wise basis. The KCC can be computed by the following formula:

$$W = \frac{\sum (R_i)^2 - n(\bar{R})^2}{(1/12)K^2(n^3 - n)},$$

where  $W$  is the KCC among given voxels, ranging from 0 to 1;  $R_i$  is the sum rank of the  $i$ th time point;  $\bar{R} = [(n + 1)K]/2$  is the mean of the  $R_i$ 's;  $K$  is the number of time series within a measured cluster ( $K=27$ , one given voxel plus the number of its neighbors) and  $n$  is the number of ranks ( $n=170$ ). The KCC program was coded in MATLAB (The MathWorks Inc., Natick, Massachusetts, USA).

### Group statistic analysis

For exploring the ReHo difference between the schizophrenic patients and controls, a second-level random-effect two-sample  $t$ -test was performed on the individual ReHo maps in a voxel-by-voxel manner. The resulting statistical map was set at a combined threshold of  $P < 0.001$  and a minimum cluster size of 162 mm<sup>3</sup>, which resulted in a corrected threshold of  $P < 0.05$  determined by AlphaSim in AFNI (Analysis of Functional NeuroImages), (B.D. Ward, <http://afni.nih.gov/afni/docpdf/AlphaSim.pdf>).

## Results

### Brain regions showed decreased regional homogeneity in schizophrenia

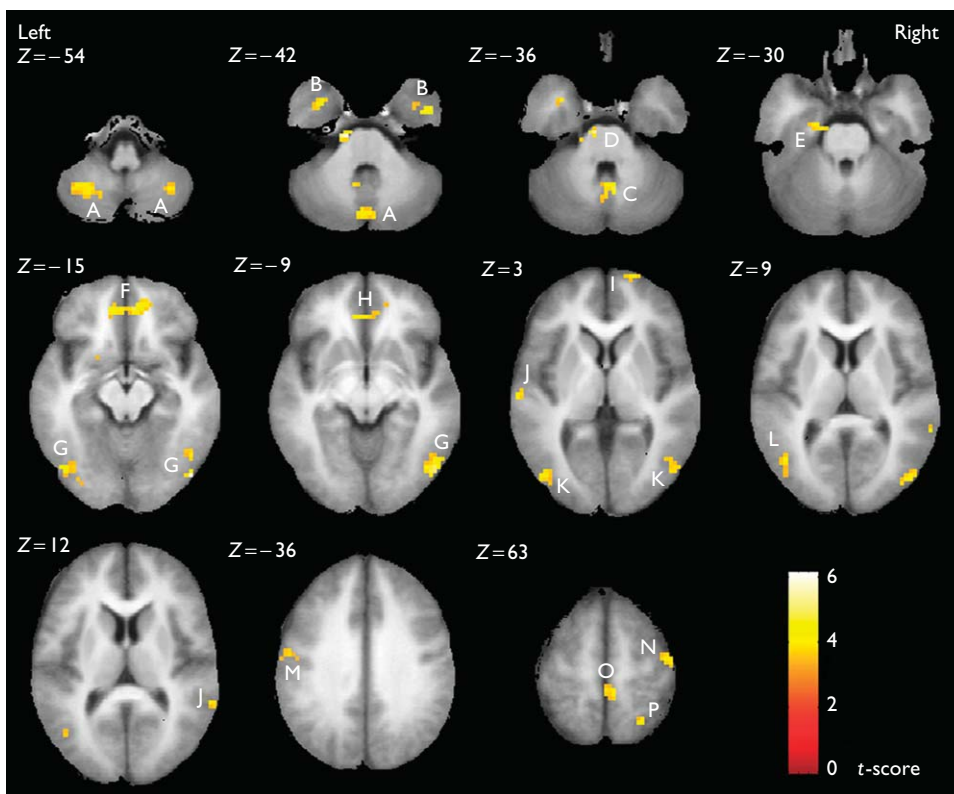
We evaluated the ReHo increase and decrease between schizophrenic patients and controls by using a two-sample  $t$ -test. Clusters with a threshold at  $P < 0.001$  and with a minimum volume of 162 mm<sup>3</sup> ( $P < 0.05$ , corrected for multiple comparisons) are thought to be significantly different between these two groups.

Schizophrenic patients showed a decrease, but no increase, in ReHo in the resting state compared with controls. The decreased ReHo was distributed over the

**Table 1** Brain regions with decreased regional homogeneity in schizophrenia

Anatomical area	Hemisphere	BA	MNI coordinates (x, y, z)	Peak t value	Z value
Superior frontal gyrus	R	10	21, 69, 3	4.02	3.61
Medial frontal gyrus	R/L	11/11	6, 45, -15/-12, 45, -18	4.79/4.77	4.16/4.15
	L	48	-21, 9, -18	4.00	3.60
Anterior cingulate gyrus	L	11	-6, 39, -6	4.58	4.02
Superior temporal gyrus	L/R	22/22	-66, -21, 6/63, -45, 9	4.70/4.02	4.09/3.61
Middle temporal gyrus	L	37	-45, -66, 9	3.93	3.55
Inferior temporal gyrus	L/R	20/20	-33, 6, -39/48, 0, -42	4.68/4.58	4.08/4.01
Parahippocampal gyrus	L	28	-18, -9, -24	3.70	3.37
Superior parietal lobule	R	7	24, -60, 63	4.21	3.75
Precuneus	R	5	3, -45, 69	3.86	3.49
Paracentral lobule	R	5	6, -39, 63	3.92	3.54
Precentral gyrus	R	4	45, -12, 63	4.24	3.77
Postcentral gyrus	L	3	-57, -9, 36	3.76	3.42
Middle occipital gyrus	L/R	19/19	-45, -78, 3/48, -78, 6	4.10/4.54	3.67/3.98
Inferior occipital gyrus	L/R	19/19	-45, -75, -18/48, -78, -15	4.82/6.15	4.18/5.01
	R	37	48, -63, -12	4.15	3.71
Cerebellar vermis	R	—	6, -60, -36	4.71	4.10
Cerebellar posterior lobe	L/R	—	-9, -57, -42/15, -51, -45	3.73/4.43	3.39/3.91
	L/R	—	-27, -60, -54/33, -60, -54	4.19/4.00	3.73/3.59
	R	—	24, -45, -48	4.13	3.69
Brainstem, pons	L	—	-9, -18, -36	5.27	4.48

R, right; L, left; BA, Brodmann area; MNI, Montreal Neurological Institute.



**Fig. 1** Brain regions with decreased regional homogeneity in schizophrenia: A, cerebellar posterior lobe; B, inferior temporal gyrus; C, cerebellar vermis; D, brainstem pons; E, parahippocampal gyrus; F, medial frontal gyrus; G, inferior occipital gyrus; H, anterior cingulate gyrus; I, superior frontal gyrus; J, superior temporal gyrus; K, middle occipital gyrus; L, middle temporal gyrus; M, postcentral gyrus; N, precentral gyrus; O, paracentral lobule; P, superior parietal lobule.

bilateral medial frontal gyrus, superior and inferior temporal gyrus, middle and inferior occipital gyrus, cerebellar posterior lobe, left hemispheric anterior cingulate gyrus, parahippocampal gyrus, middle temporal gyrus, postcen-

tral gyrus, pons of brainstem, right hemispheric superior frontal gyrus, superior parietal lobule, precuneus, paracentral lobule, precentral gyrus and cerebellar vermis (Table 1, Fig. 1).

Our results suggested that abnormal brain activity of schizophrenia may exist in the resting state, and a pattern of decreased ReHo was found in the bilateral frontal, temporal, occipital, cerebellar posterior, right parietal and left limbic lobes.

## Discussion

The ReHo is a data-driven method, which assumes that a given voxel is temporally similar to its neighbors. It measures the ReHo of the time series of the regional BOLD signal. Therefore, ReHo reflects the temporal homogeneity of the regional BOLD signal rather than its density. As the BOLD signal of fMRI may reflect neural activity [11], abnormal ReHo is possibly relevant to the changes of temporal aspects of neural activity in the regional brain, and then, ReHo may detect the brain regions with abnormal activity.

Consistent with findings of previous resting state EEG, PET and SPECT studies [4–7], our results indicated that abnormal brain activity might be widely distributed in schizophrenia during the resting state. The decreased ReHo in the frontal lobe supports the finding of reduced frontal blood flow/metabolism in resting state schizophrenia [12]. The distribution of decreased ReHo over the frontal, temporal and right parietal lobes is similar to a pattern of abnormal electrical activity in the bilateral frontal, right parietal and left temporal lobes reported in a resting state EEG study [4]. Abnormal activity of the cerebellum in resting state schizophrenia is also demonstrated in a SPECT study [7]. The brain regions described above are believed to be involved in the psychopathology and/or pathophysiology of schizophrenia [13,14].

Interestingly, the bilateral middle and inferior occipital cortex also showed decreased ReHo in resting state schizophrenia. To our knowledge, few studies report the abnormality of blood flow/metabolism in the occipital lobe of schizophrenic patients. So, the occipital lobe is used as a reference region while evaluating the blood flow/metabolism of other brain regions in PET or SPECT studies [12,15,16]. In task-related fMRI studies, however, activity deficits in the occipital cortex were observed in schizophrenic patients compared with controls [17,18]. Significant cortical thinning and gray matter density reduction within the occipital cortex of schizophrenic patients have been reported in magnetic resonance imaging studies [19,20], and correlated gray matter loss between the frontal and occipital lobes is thought to be relevant to the poor outcome (Kraepelilian) of schizophrenia [21]. These evidences support our finding that the activity of the occipital lobe may be abnormal in resting state schizophrenia.

## Conclusion

Our resting state fMRI study showed that abnormal brain activity of schizophrenic patients might exist in the resting state. The distribution of dysfunctional brain regions was similar to findings reported in previous resting state functional imaging studies. The ReHo may be potentially helpful in understanding the resting state of schizophrenia.

## References

1. Biswal B, Yetkin F, Haughton V, Hyde J. Functional connectivity in the motor cortex of resting human brain using echo-planar MRI. *Magn Reson Med* 1995; **34**:537–541.
2. Greicius MD, Krasnow B, Reiss AL, Menon V. Functional connectivity in the resting brain: a network analysis of the default mode hypothesis. *Proc Natl Acad Sci USA* 2003; **100**:253–258.
3. Zang YF, Jiang TZ, Lu YL, He Y, Tian LX. Regional homogeneity approach to fMRI data analysis. *Neuroimage* 2004; **22**:394–400.
4. Pascual-Marqui R, Lehmann D, Koenig T, Kochi K, Merlo M, Hell D, et al. Low resolution brain electromagnetic tomography (LORETA) functional imaging in acute, neuroleptic-naïve, first-episode, productive schizophrenia. *Psychiatry Res* 1999; **90**:169–179.
5. Levy AV, Gomez-Mont F, Volkow ND, Corona JF, Brodie JD, Cancro R. Spatial low frequency pattern analysis in positron emission tomography: a study between normals and schizophrenics. *J Nucl Med* 1992; **33**: 287–295.
6. Catafau AM, Parellada E, Lomena FJ, Bernardo M, Pavia J, Ros D, et al. Prefrontal and temporal blood flow in schizophrenia: resting and activation technetium-99m-HMPAO SPECT patterns in young neuroleptic-naïve patients with acute disease. *J Nucl Med* 1994; **35**: 935–941.
7. Malaspina D, Harkavy-Friedman J, Corcoran C, Mujica-Parodi L, Printz D, Gorman JM, et al. Resting neural activity distinguishes subgroups of schizophrenia patients. *Biol Psychiatry* 2004; **56**:931–937.
8. Katanoda K, Matsuda Y, Sugishita M. A spatial-temporal regression model for the analysis of functional MRI data. *Neuroimage* 2002; **17**: 1415–1428.
9. Tononi G, McIntosh AR, Russell DP, Edelman GM. Functional clustering: identifying strongly interactive brain regions in neuroimaging data. *Neuroimage* 1998; **7**:133–149.
10. Kendall M, Gibbons J. *Rank correlation methods*. Oxford: Oxford University Press; 1990.
11. Logothetis NK, Pauls J, Augath M, Trinath T, Oeltermann A. Neurophysiological investigation of the basis of the fMRI signal. *Nature* 2001; **412**:150–157.
12. Hill K, Mann L, Laws KR, Stephenson CM, Nimmo-Smith I, McKenna PJ. Hypofrontality in schizophrenia: a meta-analysis of functional imaging studies. *Acta Psychiatr Scand* 2004; **110**:243–256.
13. Kircher TT, Thienel R. Functional brain imaging of symptoms and cognition in schizophrenia. *Prog Brain Res* 2005; **150**:299–308.
14. Antonova E, Sharma T, Morris R, Kumari V. The relationship between brain structure and neurocognition in schizophrenia: a selective review. *Schizophr Res* 2004; **70**:117–145.
15. Ebmeier KP, Lawrie SM, Blackwood DH, Johnstone EC, Goodwin GM. Hypofrontality revisited: a high resolution single photon emission computed tomography study in schizophrenia. *J Neurol Neurosurg Psychiatry* 1995; **58**:452–456.
16. Erbas B, Kumbasar H, Erben G, Bekdik C. Tc-99m HMPAO/SPECT determination of regional cerebral blood flow changes in schizophrenics. *Clin Nucl Med* 1990; **15**:904–907.
17. Johnston PJ, Stojanov W, Devir H, Schall U. Functional MRI of facial emotion recognition deficits in schizophrenia and their electrophysiological correlates. *Eur J Neurosci* 2005; **22**:1221–1232.
18. Tregellas JR, Tanabe JL, Miller DE, Ross RG, Olincy A, Freedman R. Neurobiology of smooth pursuit eye movement deficits in schizophrenia: an fMRI study. *Am J Psychiatry* 2004; **161**:315–321.
19. Narr K, Toga A, Szeszko P, Thompson P, Woods R, Robinson D, et al. Cortical thinning in cingulate and occipital cortices in first episode schizophrenia. *Biol Psychiatry* 2005; **58**:32–40.
20. Ananth H, Popescu I, Critchley H, Good C, Frackowiak R, Dolan R. Cortical and subcortical gray matter abnormalities in schizophrenia determined through structural magnetic resonance imaging with optimized volumetric voxel-based morphometry. *Am J Psychiatry* 2002; **159**:1497–1505.
21. Mitelman S, Buchsbaum M, Brickman A, Shihabuddin L. Cortical intercorrelations of frontal area volumes in schizophrenia. *Neuroimage* 2005; **27**:753–770.